

A Case Report on Placental Chorioangioma

Anuja Sachapara¹, Neha Agarwal², Vaishali Taralekar³

How to cite this article:

Anuja Sachapara, Neha Agarwal, Vaishali Taralekar/A Case Report on Placental Chorioangioma/Indian Journal of Maternal-Fetal & Neonatal Medicine; 9(2):85-87.

Authors Affiliation:

¹Third Year Postgraduate Resident, ²Senior Resident, ³HOD, Department of Obstetrics and Gynecology, Bharati Vidyapeeth, Pune, Maharashtra 411030, India.

Correspondence Author:

Vaishali Taralekar, HOD, Department of Obstetrics and Gynecology, Bharati Vidyapeeth, Pune, Maharashtra 411030, India.

E-mail: vaishutaralekar@gmail.com.

Received on: 29.8.2022

Accepted on: 30.10.2022

Abstract

Introduction: Placental chorioangioma is the most common benign tumour of the placenta. It is a vascular mass arising from chorionic tissue. It is a relatively rare condition that can result in serious prenatal complications and adverse pregnancy outcome. We report a case of 27 year old G2P1L1 with 28 weeks of gestation with severe pre-eclampsia with FGR and ultrasonography suggestive of chorioangioma of size 3x2.4 cm. Histopathology confirmed the diagnosis. This patient despite having small tumour and being diagnosed late at 28th week of gestational age had an unfavourable fetal outcome.

Keywords: Placental chorioangioma; Pre-eclampsia; IUD.

INTRODUCTION

Placental chorioangioma is the most common benign tumour of the placenta.¹ It is a vascular mass arising from chorionic tissue which is encapsulated, solitary and intraplacental. Generally small ones are uncomplicated and chorioangioma >5 cm are associated with adverse maternal and fetal outcome. Chorioangioma is believed to arise by 16th day of fertilization, although there is no documentation of tumour in first trimester.²

CASE REPORT

A 27 year old second gravida, with 6.5 months of pregnancy with previous LSCS, referred with complaints of PV bleeding since 1 hour, soaking 1 pad, associated with passage of clots. No other

complaints like headache, blurring of vision, vomiting, and epigastric pain. Her LMP was 4/10/21 and she had previous regular cycles. Her antenatal period was uneventful. On examination her blood pressure was 190/110 mm Hg, per abdominally uterine height was 28 cm, tone raised, and fetal heart sounds not found on Doppler, no scar tenderness. On Per speculum examination active bleeding was present.

After stabilization we further investigated the patient, all labs like hemogram including platelet count, renal and liver function test, LDH, coagulation profile were sent and found to be within normal limit. Her urgent ultrasonography was done which was suggestive of intrauterine fetal death of 26 weeks with fetus weighing 400 grams. Placenta is anterior and not low, 4 cms away from os. There

was a chorioangioma of 3x2.4 cm and uterine artery Doppler suggesting of mildly increased resistance.

All her previous lab reports were normal. She did not having regular ANC visits.

Decision to terminate the pregnancy was taken and she was induced with Tab misoprostol 50 mcg S/L every 3 hourly-> total 3 doses given.

She delivered baby girl of 385grams. Placenta was sent for histopathology. Gross examination of placenta was done, weighing 400 grams, 15*10*3 cms. Maternal and fetal surface are grossly unremarkable. A tumor, cystic in appearance of 3*3.4 cm noted. On microscopic examination placental chorioangioma with lakes of blood vessels seen.

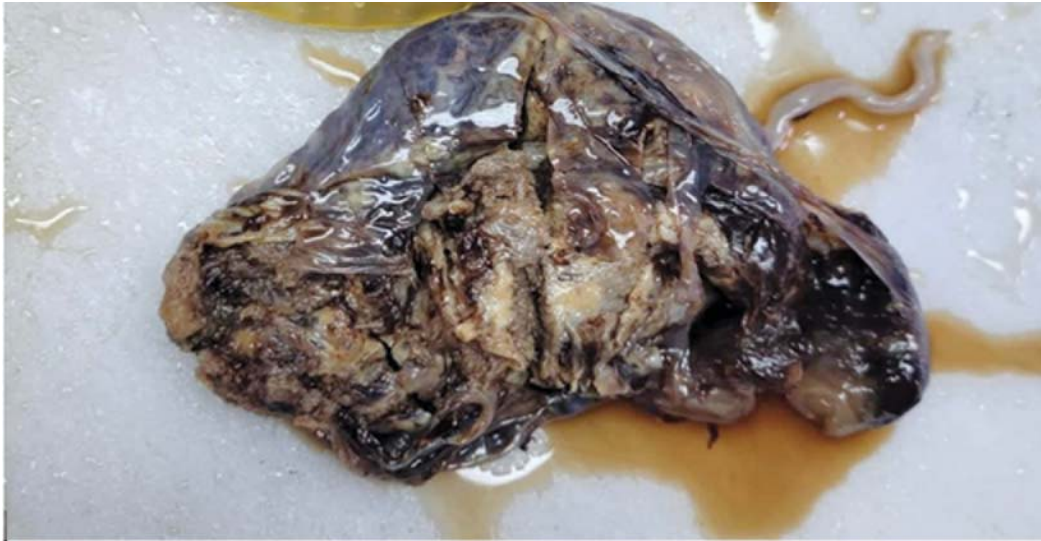

Fig. 1: Showing gross appearance of placental tumor.

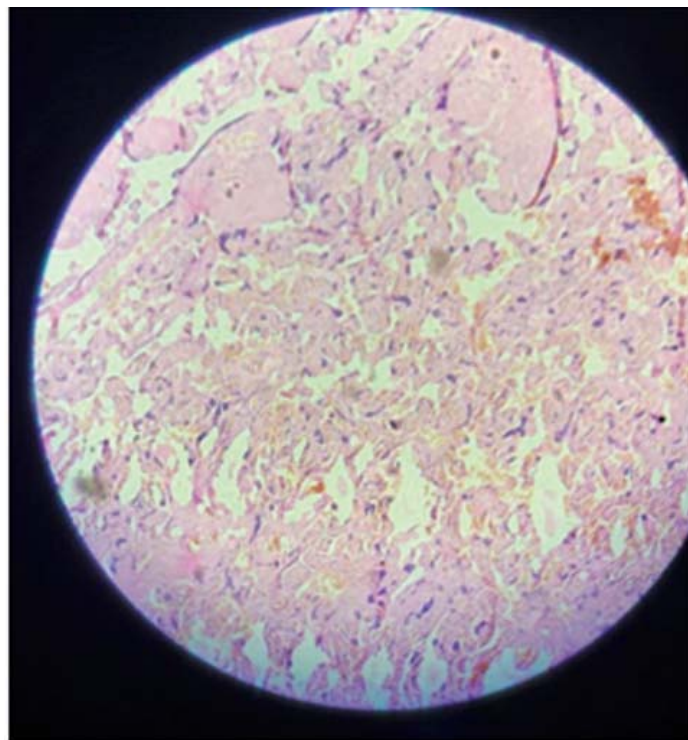


Fig. 2: showing microscopic image of chorioangioma with lakes of blood vessels.

DISCUSSION

Placental chorioangioma is the most common benign tumour of the placenta. It is a vascular mass arising from chorionic tissue. It is a relatively rare condition that can result in serious prenatal complications and adverse pregnancy outcome. The largest retrospective study of 22,000 placental examinations showed 138 chorioangioma with an incidence of 0.6%.³ Multiple pregnancies and female babies are more associated with placental chorioangioma.

Small chorioangiomas are asymptomatic but large placental chorioangioma is associated with adverse maternal complications like polyhydramnios, preterm labour, rarely pre-eclampsia and early separation of placenta, ante partum haemorrhage and adverse fetal outcome such as fetal growth restriction, fetal anaemia and fetal hydrops rarely intrauterine fetal death due to pre-eclampsia or abruption.

Diagnosis of placental chorioangioma is done from first trimester scan and in subsequent scan size of chorioangioma will be closely monitored on ultrasound.

As increasing size is associated with rare complications, counselling of couple is must and they should be aware of all the signs and symptoms for timely intervention.

There are several modalities of treatment published till date, with various results. This

includes endoscopic laser coagulation of feeding vessels, alcohol injection, micro coil embolization and therapeutic amnio drainage.⁴

CONCLUSION

Our patient had an unfavourable outcome despite of having small placental chorioangioma, due to irregular ANC visit. Close surveillance will help in correct diagnosis and anticipation of complications.

Preeclampsia leading to abruptio placenta is a rare outcome of placental chorioangioma. Prompt antenatal visits and diagnosis of chorioangioma with ultrasound+doppler will help in reducing adverse fetal outcome and maternal morbidity and mortality.

REFERENCES

1. Gowri Vaidyanathan, Aneeta Bai, Jaykumari Perchani, Hana El Said, Ritu Lakhtakia *Journal of Case Reports* 2017;7(1):30-32.
2. L. A. Bracero, M. Davidian, and S. Cassidy, *Chorioangioma: diffuse angiomatous form*. 1993-09-18-11 *Chorioangioma: diffuse angiomatous form* Bracero.
3. P. Kuhnel, "Placental chorioangioma," *Acta Obstetrica et Gynecologica Scandinavica*, vol.13, pp. 143-145, 1933.
4. Inas Babic, Maha Tulbah & Wesam Kurdi, *Journal of medical case reports*, article number :183(2012).

