

Principles of Digit Replantation

Barath Kumar¹, Ravi Kumar Chittoria²

How to cite this article:

Barath Kumar, Ravi Kumar Chittoria, Principles of Digit Replantation. Indian Journal of Legal Medicine. 2022;3(1): 9-12.

Abstract

Amputations of the fingers are common life altering injuries encountered in the casualty. They can result from a variety of injuries, but they are most commonly caused by power tools or machines in the workplace. Surgeons have been able to successfully reattach fingers that have been amputated at the level of damage using modern micro vascular surgical techniques. In this article we will discuss about the principles of digit replantation.

Keywords: Principles; Digit replantation; Amputations.

INTRODUCTION

Digit amputations are in the increasing trend due to the increase in the small scale factories to large scale industries. Most of the injuries occurred due to unexpected accidents. In paediatric age amputations are due to the handling of the sharp instruments while playing at home without the supervision of parents and other unexpected events. First revascularization of a partially amputated finger was done by Kleinert (1963) and First digital replantation was done by Komatsu & Tamai, Japan (1965). Amputated thumbs, multiple

digit amputations, and single digit amputations distal to the FDS insertion, as well as all amputations in children, are currently advised for replantation.¹ Replantation surgery is a technically challenging procedure. Patient selection, rigorous operating technique, and postoperative monitoring are all critical to success. In the majority of cases, the replanted digit has at least protective feeling and usable range of motion. Patient satisfaction after replantation is high, despite problems such as joint stiffness, tendon adhesions, mal-union, and cold sensitivity. In this article we will discuss the principles of digit replantation.

Anatomy

The zone of flexor tendon injury influences the level of amputation. Transections that occur distal to the origin of the flexor digitorum superficialis tendon are classified as Zone 1 injuries (Fig. 1). Zone 2 injuries occur between the flexor digitorum superficialis distal insertion and the A1 pulley, which is just proximal to the meta-carpophalangeal joint (Fig. 2). Between the A1 pulley and the distal margin of the carpal tunnel, Zone 3 flexor tendon

Author Affiliation: ¹Senior Resident, ²Professor, Department of Plastic Surgery, Jawaharlal Institute of Postgraduate Medical Education and Research Pondicherry 605006, India.

Corresponding Author: Ravi Kumar Chittoria, Professor, Department of Plastic Surgery, Jawaharlal Institute of Postgraduate Medical Education and Research Pondicherry 605006, India.

E-mail: drchittoria@yahoo.com

injuries and amputations occur. Carpal tunnel injuries are classified as Zone 4 ailments (Fig. 3). Amputations in Zone 5 and flexor tendon injuries occur close to the carpal tunnel. Only the flexor digitorum profundus tendon is removed in Zone I amputations, leaving the proximal interphalangeal joint mobility intact (PIP). Amputations at this level usually result in a positive outcome. The tiny diameter of the digital arteries may prevent

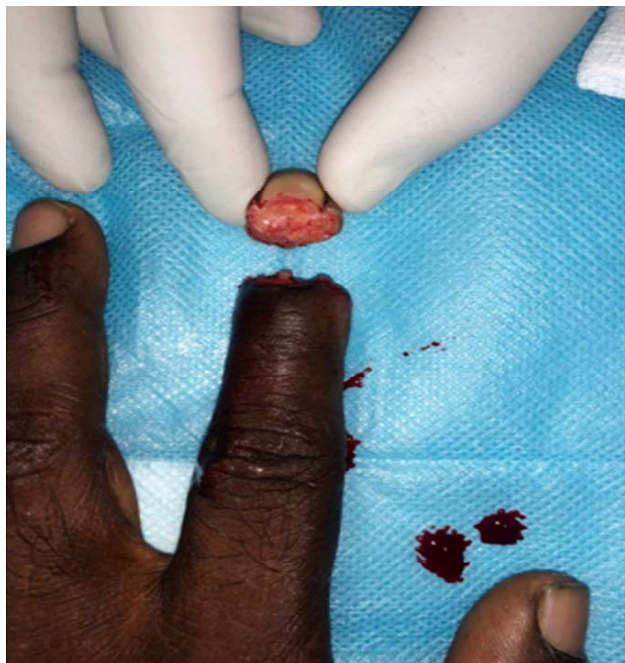


Fig. 1: Zone 1 amputations.

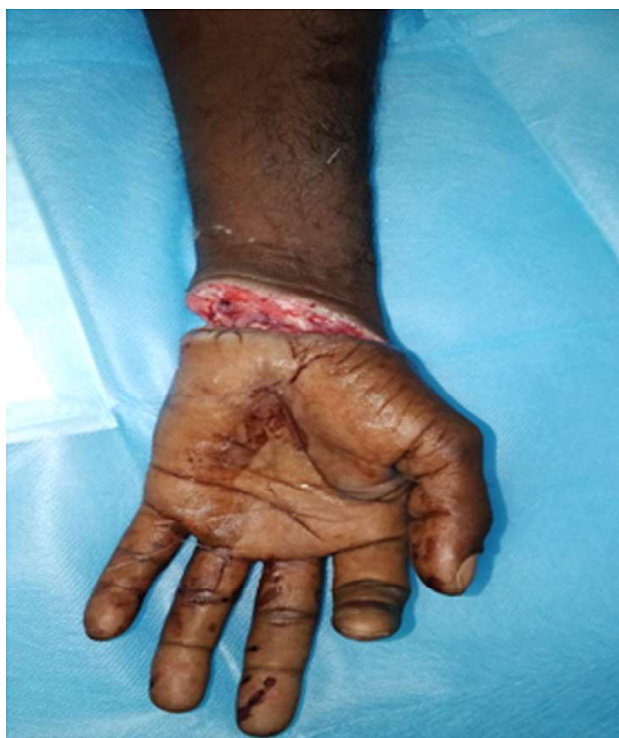

Fig. 3: Zone 4 Near total amputation.

replantation if the amputation occurs at the distal aspect of the middle phalanx or past the distal interphalangeal joint (DIP). Amputations at this level have historically had a bad prognosis due to the repair's inability to pass through the intricate digital pulley system. Amputations in Zone 2 are not absolute contraindications to replantation and should be considered in carefully selected individuals.²

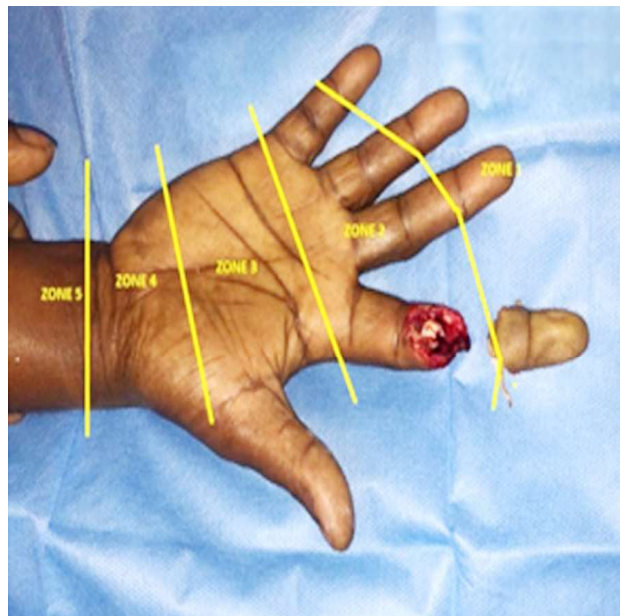


Fig. 2: Zones of amputations based on flexor tendons zone 2 amputation.

Equipment

An operating microscope, microsurgical equipment, and suture are required for digit replantation. If the treating facility lacks this equipment, the patient may need to be transferred to one that does. The above mentioned equipment are basic necessary for the digit replantation. Sutures used in digit replantation were 9'0 -10'0 Nylon sutures.

Personnel

Plastic surgeons trained in microsurgery and hand replantation can do digit replant. Any attending orthopaedic or plastic surgeon would receive this training. However, this method necessitates specialised equipment and personnel. The above facilities and requirements are necessary for the successful digit replantation.

Handling of Amputated Extremity Parts

Microsurgery is required for replantation, and it must be done within a few hours of the part's

amputation, at a facility with specialised equipment, surgeons, and support staff. To increase the odds of a successful replantation, the amputated digit should be stored in a cool (near to freezing, but not below freezing) and sterile or clean environment as soon as feasible. Wrap moistened gauze around the parts and place them in a clean or sterile bag floating in freezing water. Dry ice should not be utilised since it can cause tissue to freeze. There are sterile "Amputate-Bags" on the market that help with dry, cold, and sterile preservation. As surgeons gain greater experience with microvascular procedures and reduce the operational reasons for replantation, patient outcomes and digit viability have improved. Transportation of the amputated part is important in preserving viability. The most widely utilized and effective method of preservation is wrapping the amputated extremity in gauze moistened with a physiologic solution (normal saline or lactated ringers), placing the wrapped amputated part in a plastic bag, then putting this plastic bag on ice. Alternatively, the part may be immersed in a physiologic solution in one bag, which is then placed on ice. Amputated extremity parts should never be placed directly on ice, as this may result in frostbite or other soft tissue injuries to the amputated part. Such damage may preclude replantation altogether or compromise the achievable functional result of replantation.³

Indications for replantation

1. General indications for upper extremity replantation are thumb amputation, multiple digit amputation, mid-palm (trans-metacarpal) amputation, single-digit amputations distal to the insertion of the flexor digitorum superficialis tendon.⁴
2. Sharp amputations at the hand, forearm, or elbow level, and any amputation in a child.

Contraindications

- Severe Crush or Avulsion Injuries (Fig. 4),
- Multiple Level Injuries,
- Single Finger Amputation Proximal to the Insertion of The Flexor Digitorum Superficialis Tendon (Proximal To Zone 1),
- Prolonged Ischemia Time, And
- Mentally or Physically Unstable Patients.

Patients with absolute contraindications to replantation do not need emergent transfer to a replant capable facility if their wounds are otherwise

manageable at the facility of initial presentation.

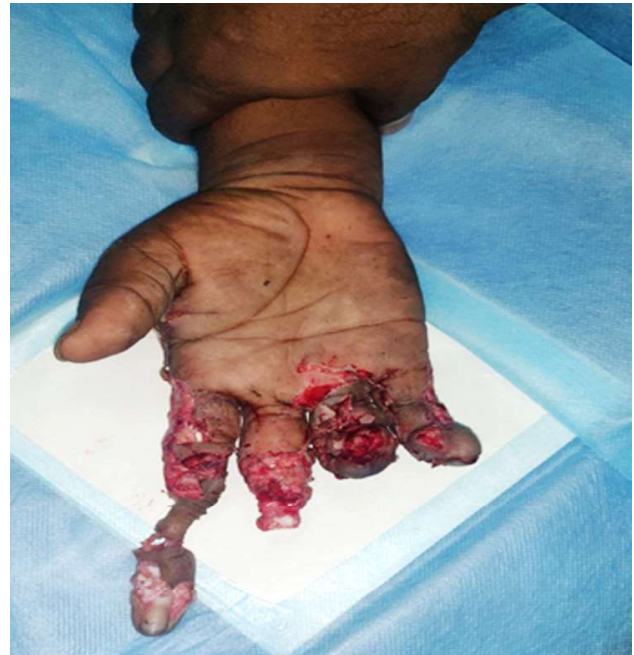

Fig. 4: Crush injury of the hand causing multiple amputations.

ISCHEMIA TIME

Timing is critical in replantation surgery. The amount of muscle in the amputated part determines the amount of ischemia time each part will tolerate. Digits contain no muscle, and the bone and soft tissue present in each digit have a relatively low metabolic rate and formation of toxic by products of ischemia. Digits amputated in Zone 1 and Zone 2 may tolerate up to 12 hours of warm ischemia time and up to 24 hours of cold ischemia time. In general, muscle makes up a substantial portion of the soft tissue in Zone 3 to 5 amputations. Extremities amputated at this level will tolerate no more than six hours of warm ischemia time or 12 hours of cold ischemia time. Because of this, vascular shunting to the amputated part may be necessary for forearm or elbow amputations before initiating the surgical repair.⁴

SEQUENCE OF IMPLANATATION

The amputated part will be taken to the operating room before the patient arrives the operation theatre for thorough wound debridement and examination under the microscope for removal of dirt and to identify the digital vessels and nerves for replantation. The quality of the tissue, specifically

the nerves and blood vessels, are examined before proceed to the replantation. The identifiable structures should be marked with suture or micro clips for anastomosis. The first step in replantation is bone shortening and fixation of the bone. The bone should be shortened adequately to take all tension off of the subsequent soft tissue repairs. In the paediatric population, any bony shortening should be done without injuring the physis. Bony fixation is followed by extensor tendon repair then flexor tendon repair. The surgeon should then initiate arterial repair. No matter the level of amputation, anastomosing intact and healthy arterial intima on each side of the repair is important criteria to success. If the excessive artery and vein are damaged, vein grafts are necessary. The vein grafts are usually taken from the ipsilateral extremity in the cephalic or basilic vein. However, lower extremity vein grafts may be necessary. Nerve repair is the next step, followed by vein repair. Lastly, the surgeon completes soft tissue coverage of the repair.^{5,6}

Order of Repair

- Bone
- Extensor tendon
- Flexor tendon
- Artery
- Nerve
- Vein
- Soft tissue

COMPLICATIONS

Bleeding, infection, replant failure, and finger stiffness can accompany flexor tendon injuries. Venous congestion of the finger is prevalent due to poor anastomosis of injured dorsal veins. Some methods for treating or preventing venous congestion include removing the nail plate, making fish mouth incisions over the fingertip, and applying heparin pledgets.⁷ Aeromonas hydrophilia infection can occur when using leech therapy.

OUTCOME

Hand surgeon, plastic surgeon, emergency

department physician, and speciality nurses are needed for digit replantation. Once transplanted, the digit must be closely monitored for ischemia and infection. Patients need physical therapy after surgery to regain joint function and strength. Attainment of viability and function of the digits needs expertise in the field of digit replantation. The facilities are not available widely at all centres at ease for the digit replantation. Early referral and proper transport of the amputated digits plays a major role in replantation.

Conflicts of interest: None

Authors' contributions: All authors made contributions to the article

Availability of data and materials: Not applicable.

Financial support and sponsorship: None.

Consent for publication: Not applicable

REFERENCES

1. Lee DC, Kim JS, Roh SY, Lee KJ, Kim YW. Flap Coverage of Dysvascular Digits Including Venous Flow-Through Flaps. *Hand Clin.* 2019 May; 35(2):185-197.
2. Pet MA, Ko JH. Indications for Replantation and Revascularization in the Hand. *Hand Clin.* 2019 May; 35(2):119-130.
3. Long C, Suarez PA, Hernandez-Boussard T, Curtin C. Disparities in Access to Care Following Traumatic Digit Amputation. *Hand (N Y).* 2020 Jul;15(4):480-487.
4. Johnson SP, Drolet BC. Revascularization and Replantation in the Hand: Presurgical Preparation and Patient Transfer. *Hand Clin.* 2019 May;35(2):109-117.
5. Milone MT, Klifto CS, Lee ZH, Thanik V, Hacquebord JH. Relationships Between Vein Repairs, Postoperative Transfusions, and Survival in Single Digit Replantation. *Hand (N Y).* 2020 Jul;15(4):488-494.
6. Shaterian A, Rajaii R, Kanack M, Evans GRD, Leis A. Predictors of Digit Survival following Replantation: Quantitative Review and Meta-Analysis. *J Hand Microsurg.* 2018 Aug;10(2):66-73.
7. Tang JB, Wang ZT, Chen J, Wong J. A Global View of Digital Replantation and Revascularization. *ClinPlast Surg.* 2017 Apr;44(2):189-209.