

Medicolegal Autopsy and Post-Mortem Examination in Female Victims of Crime: When and Why

Vivekanshu Verma¹, Mahipal Singh Sankhla², Rajeev Kumar³, Santosh Kumar Verma⁴

¹Associate Consultant, Emergency and Trauma Care, Medanta the Medicity, Gurugram, Haryana 122001, India. ²Research Scholar, ³Associate Professor, Department of Forensic Science, Galgotias University, Noida, Uttar Pradesh 203201, India. ⁴Senior Advocate, Rajasthan High Court, Jaipur, Rajasthan 302005, India.

How to cite this article:

Vivekanshu Verma, Mahipal Singh Sankhla, Rajeev Kumar, *et al.* Medicolegal Autopsy and Post-Mortem Examination in Female Victims of Crime: When and Why. Indian Journal of Legal Medicine. 2020;1(2):65-73.

Abstract

In Medicolegal Autopsies, Post-Mortem Reports (PMR) are documents prepared by a Registered Medical practitioner (RMP), pertaining to injury, sexual offence, suspected poisoning or unexplained death. To perform a medico-legal autopsy, consent from the relatives of the deceased is not required. This review article deals with the purpose of the inquest and roles of the medico-legal autopsy in young female victims of crime.

Keywords: Inquest; Medicolegal Autopsy; Sexual assault; Abortion, etc.

Introduction

The term 'Autopsy' originates from ancient 'Autopsia' which is derived from 'Autos' i.e. 'Oneself' and 'Opsis' i.e. 'to see for oneself'. An autopsy is frequently done in cases of sudden death where a doctor is not able to give a death certificate or when death is believed due to an unnatural cause.

PMR contains all the facts, observed by the doctor and his opinion drawn therefrom. Doctor's opinion must be based upon the clinical observations made by him/her, and not on hearsay evidence. All deaths due to unnatural causes and deaths that are believed to be due to natural causes but where

the medical cause of death is not certain or known are subjected to an inquest. The objective of an inquest is to ascertain facts pertaining to the death. This is achieved by inquiry and at the conclusion of the inquest a verdict is arrived as to whether the death was due to a natural, accidental, suicidal or a homicidal cause. A PMR may become necessary in certain deaths that come up for inquests. In these situations the authority which conducts the inquest will order a doctor to prepare a PMR in medico-legal autopsy.

Section 174 and 176 Code of Criminal Procedure (Cr.P.C.) mention the concept of a medico-legal autopsy during the investigations of a sudden, suspicious, unnatural death. The objective of medicolegal post-mortem examination is to establish the identity of a body, when not known; to ascertain the time since death and the cause of death; and whether the death was natural or unnatural and if unnatural, whether it was homicidal, suicidal or accidental. In case of new born female infants, the question of live birth, dead born, still-birth and viability assume importance and should be determined.

Purpose of postmortem examination in a particular case of unnatural or suspicious death is to find out the following-

- To know the exact cause of death.
- To find out the circumstances of death
- To find out the postmortem interval.
- In case of the unidentified dead body, to establish the identity of the deceased or to help to do so.

Corresponding Author: Vivekanshu Verma, Associate Consultant, Emergency and Trauma Care, Medanta the Medicity, Gurugram 122001, India.

E-mail: vivekanshu@yahoo.co.in

- The period for which the deceased survived after sustaining injuries or exposure to the poison.
- To know the nature or the manner of death, whether natural, suicide or homicide.
- Type of weapon or the poison used.
- Whether one or more than one person was involved, in case of homicide.
- Whether any natural disease process contributed in any way, to cause the death.
- Whether any other offence was related with the death e.g. rape.
- Is the injury, which has caused death, expected to cause death in ordinary course of nature.
- Whether the dead body has been displaced from the original place of disposal.
- To know whether more than one method or weapon were used or if more than one person were involved in the crime.
- Whether the deceased received any treatment before death.
- Whether there is anything on or with the dead body which may help identification of the assailant
- In case of death due to assault, the relative positions of the victim and the assailant.

Medicolegal issues are resolved by Postmortem Examination

Forensic Experts are well aware of minor trauma sometimes leading to death either immediately or shortly after. Careful examination of such cases may reveal some other underlying conditions, such as an existing disease or a vascular abnormality that had contributed to or aggravated the death. A punch on the front of the chest may kill a person who is suffering from advanced coronary artery disease, and this can only be established by a postmortem examination. It is a well-established fact that alcohol and drugs have not only contributed to all types of accidents but even to death. A body lying on a rail tract or a highway with injuries does not necessarily mean that the victim had died of an accident. A body found burnt inside a building does not always mean that the death was due to burns." The following example illustrates the need for a postmortem examination in road accidents. A private bus crashed into a tree in the night. The occupants consisted of the driver, conductor and a few passengers. The conductor

died as a result of the accident while the others survived. At autopsy, the distribution and pattern of injuries found on the conductor suggested that he was actually driving the vehicle, and without a seat belt as well. In addition he had alcohol in his blood, which was above the legal limit. On the other hand, the injuries found on the driver who survived were that of an unrestrained front seat passenger. It became evident that the actual person who drove the bus at the time of the accident was the conductor. A cover up story had been made by interested parties because the conductor, who actually drove the bus, not only did not possess a driving license but had consumed alcohol. These facts when made known would naturally interfere with the insurance payment. The fact that a seat belt was not used also result in reduced insurance payment as it could be considered as contributory negligence.

List of Reasons for Medicolegal autopsies in young females

- Autopsy of Sexual assault victims- adults and children.
- Autopsy of Burn victims.
- Death during delivery.
- Perinatal deaths.
- Death on table during gynaecological surgeries.
- Death during abortion.
- Autopsy in Poisoned females with suspected murder.
- Dowry deaths Death of Recently married females within 7 years of marriage.
- Autopsy in death of females due to negligence.

Rules of Medicolegal Autopsy in India:

- Written order from the Police Officer.
- Day time.
- In the Hospital Where the dead body lies.
- Identity of the deceased to be established.
- The great cavities opened (Cranial, Thoracic and Abdominal).
- Writing post mortem report on the spot.

Postmortem is done in every Burn Case victim to find out:

- a) To find out the actual cause of death.

- (b) To find out the time passed since death to corroborate the day of crime.
- (c) To identify of the deceased, in cases where it is unknown unclaimed (Nitish Katara murder case - blunt injury head by hammer - RTA - Burn- can't identify).
- (d) To find out the Burn injury on body before death / after death.
- (e) To collect relevant information to assist the investigating Officers to arrive at a conclusion whether death is accidental, suicidal or homicidal.
- (f) In case of infants born in burned pregnant, whether it is live born / still born / dead born and if live born the period of survival and the cause of death.
- (g) To collect evidence- pieces of vital organs and samples of blood and body fluids and foreign bodies- Gunshot bullets- to establish the weapon of crime.
- (h) To opine as to whether medical attendance following burn injury was given or not (Kennedy phenomenon) -In VIP cases, eg., John F Kennedy's murder and Indira Gandhi's murder- suturing and repair of wound vanished the track of gunshot wound - but still culprit was found guilty.
- (i) To ascertain the period of survival following receipt of Burn injury.
- (j) To find out the time passed since death since last meal (poisoned before burn).
- (k) Whether the position of the dead body was changed or dragged after death.
- (l) To opine as to the place and circumstances of death - basing on detection of modified forms of putrefaction.
- (m) In presence of multiple injuries - what was the number of assailants (Nirbhaya case of delhi).
- (n) To connect the accused with the offence (Priyadarshini Mattu Murder case).
- (o) To collect samples for chemical analysis, histological exam.
- (p) To opine as to whether medical attendance following injury was beneficial or deleterious, thus causing death due to medical negligence.

Case report of Cremation (without postmortem) in sudden death of young married female.

Burned - Cremation of married female after killing by poisoning by her husband (in demand

of dowry), Husband took deceased to Doctor, who declared her brought dead but didn't informed police and handed over body without postmortem. Later parents of victim filed FIR and made doctor as culprit in helping the accused husband in disposing the dead body of victim. Doctor was arrested and imprisonment for 3 years for helping accused in destruction of evidence by burning the deceased without Postmortem.

Medical records in Burn Case

Medical records are acceptable as per Section 3 of the Indian Evidence Act, 1872 amended in 1961 in a court of law. These are considered useful evidence by the courts as it is accepted that documentation of facts during the course of treatment of a patient. The patient or their legal heirs can ask for copies of the treatment records that have to be provided within 72 hours.

How Long Medical Records should be Preserved?

Under the provisions of the Limitation Act, 1963 and Section 24A of the Consumer Protection Act 1986, which dictates the time within which a complaint has to be filed, it is advisable to maintain records for 2 years for outpatient records and 3 years for inpatient and surgical cases (Medical Council of India Regulations 2002 guidelines).

Medico-legal cases should be maintained until the final disposal of the case even though only a complaint or notice is received.

Case Report of Self-inflicted Burn to blame her Husband: Plastic surgeon's court evidence

An 18 year old woman filed a complaint at the city magistrate's court at lucknow that she was burnt by her husband with a pair of tongs, in demand of dowry. As per Plastic surgeon's opinion on prescription, She had several small marks of superficial burns causing redness & vesication on the wrist, forearms, legs & thighs. Some of these have the shape of the knob of the tongs. During the court trial, it was found that they have been self-inflicted, in as much as they are approachable by the woman herself. It was found that she had inflicted the burns to strengthen her case for divorce from her husband, as she was in love with her boyfriend.

Incendiary Warfare involves the technique of firebombing which is designed to damage the target, generally an urban area, through the use of fire, caused by incendiary chemicals (Napalm, white phosphorus, thermite) which catches fire on exposure to air, thus its intentional pre-planned man-made disaster, simulating fire accident.

Incendiary Warfare: firebombing terrorism: Successful case of survival by plastic surgery.

The Kim Phuc story: the 10 years old victim was residing with her family in Vietnam, which was attacked by American planes supporting Vietnam war in 1972, dropping incendiary bombs, causing massive fire. The victim was badly burnt and tore off her burning clothes. Her black and white photo of running naked crying on road with Vietnamese soldiers and fire-smoke in background became one of the most haunting images of history of Vietnam war, which later won Pulitzer prize, and led to shut down of American interference and support in war. The victim's burns were so severe that she probably could not survive. After a 14 month Hospital stay and 17 surgical procedures by plastic surgeons at Barsky Hospital Saigon, including skin transplantation, however, she was able to return home alive.¹³

Postmortem Burn: a misleading finding in PMR

The absence of the ante-mortem signs of burns on the body of the deceased provides enough evidence for it being a post-mortem burn. Sooth of blackening in trachea suggest inhalational burns of antemortem nature. Reparative processes, such as signs of inflammation (red line), formation of granulation tissue pus and sloughs, will indicate that burn was caused during life. The line of redness being a vital reaction in antemortem burns persists even after death and absent in post- mortem burns. Histopathology and histochemistry can prove the antemortem nature.

Questions asked to Doctor by Police/lawyer/Judge in court of law in Burn case

1. Whether the smell of inflammable material (petrol/ kerosene) was appreciated at the time of arrival in Hospital?
2. Whether the burnt clothes were on the body of the victim at the time of admission? If yes, did Doctor preserved the burnt clothes in sealed packet for Forensic science laboratory for identification of inflammable petroleum substance, if any? If not, its comes under destruction of evidence of crime by duty doctor.
3. What is the mode of Burn, as per history, examination?
4. What are the lesions found due to burning or scalding or corrosives?

5. What was the percentage of total body surface area involved with burn?
6. Is there any spared area of the body not affected by burn? Eg., Thumbs, fingers, palms, soles. Thumb impression and mark of identification written in MLC are difficult to get in burn cases.
7. Was the Burn victim pregnant at the time of incidence? What was the impact of burn on pregnancy, did burn injury resulted in abortion?
8. If the burn is an accident at workplace, what is the percentage of permanent disability caused to claim monetary compensation under Employees' Compensation act for death on whether it was in the course of employment or suicidal attempt by the employed person?
9. Can this injury be caused by fall on hard and blunt surface? Brush burn.
10. Was it Ante-mortem or post-mortem Burn in victim brought dead in emergency?

Intention of Doctor & its relevance in medicolegal cases

Burns is a three dimensional injury. Burn injuries present challenging problems to the Dermatologist and Plastic Surgeon, as dermatologists use lasers for dermal disorders, thus can cause iatrogenic burns on overexposure, thus requiring plastic surgery care. The principal issue usually is causation, particularly when a distinction is to be made between an accident and a deliberate act. Court of law judges the intention of doctor while deciding the case of medical negligence or wrongful act by doctor. Burn is a double edged sword in which intention of doctor is differentiated by the law during investigation.

In view of the increasing number of dowry deaths, guidelines have been laid down by the Government of India for examination of such cases, and the law in respect thereof has been suitably amended. The Indian Penal Code (I.P.C.), Criminal Procedure Code (Cr.P.C.) and Indian Evidence Act (I.E.A.) are amended as per the criminal law (Second Amendment) Act, 1983 and was approved by President of India to deal effectively with cases of dowry deaths and also the cases of cruelty to married women by their in laws.

Dowry death and legal protection of women in India; All D's for easy recall

Domestic Violence by Burn on married women and legal protection of women in India.

D- Domestic Violence (DV) Protection Act 2005.

D- Dowry Prohibition Act, 1961.

D- Deceased's - Sati (Prevention) Act, 1987- Sati means the act of burning or burying alive any widow with the body of her Deceased husband, irrespective of whether such burning is claimed to be voluntary on the part of widow.

D- Dowry Death - 304B IPC- Non-bailable offence - within 7 years of marriage- 7 years punishment- killing by in-laws and simulating it accident - D- Dry heat fame burn while cooking in kitchen stove of kerosene.

D- Domestic cruelty: 498A IPC: physical by burn /chemical torture by acid burn.

Case Law on IPC Section 304A: Accidental death due to negligence while cooking (unintentional). When questioned, the deceased has reported to her that she got injured due to bursting of stove while she was cooking. Doctor had conducted the postmortem, and he did not find any blisters in mouth of the deceased. Police officer deposed that investigation did not disclose that the accused had harassed or ill-treated the deceased prior to her death. Citation: Venkatesan Vs Rani, 2013 (8) Cri

LJ 4208 (SC);208 2013(10) Scale 442: AIR 2013 SC 3320 (SC).

IPC Section 304 - B deals with dowry death. When the death of a married woman is caused by any burns or bodily injury or occurs under abnormal or suspicious circumstances within seven years of her marriage duration and it is clearly shown that soon before her death she was subjected to cruelty or harassment or torture by her husband or any relative of her husband or in laws for, or in connection with, any demand for dowry, such death shall be called as "dowry death", and such husband or relative or in law s deemed to have caused her death. Whoever commits dowry death shall be punished with imprisonment for a term minimum of seven years which may extend to imprisonment for life.

IPC Section 498 - A: deals with husband or relative of husband of the subjecting her to cruelty

Whoever being the husband or the relative of the husband or in law of a woman, subjects such woman to cruelty or harassment or torture shall be punished with imprisonment for a term which may extend up to three years and shall also liable to pay fine. The cruelty can be either mental or physical torture which drives the women to commit suicide or to cause serious injury, or danger to life or health.

Postmortem re-examination or second autopsy of a dead body at times may be required under

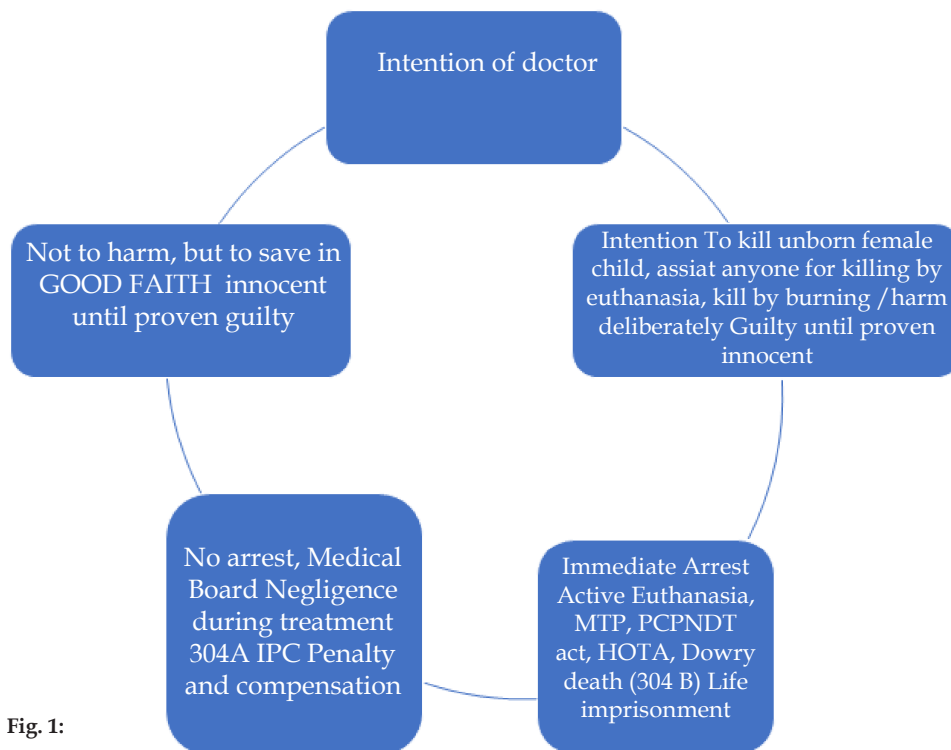


Fig. 1:

certain circumstances before cremation or after exhumation. The interpretation of the findings of a second autopsy, performed on a previously autopsied body, is not an easy task for the autopsy surgeon due to various artifacts and alterations resulting from the first autopsy and it is usually demanded or ordered under public cry or political overtones.

Recent infamous case law, which was solved by meticulous documentation by the duty doctor during MLR and PMR writing.

Nirbhaya case: Landmark case of MLR and Autopsy of Sexual assault victim, which brought Criminal law amendment in laws related with gangrape.

Case facts: in 2012, A young paramedic student was gangraped in a moving bus and physically mauled grievously, and in inspite of best of care, she succumbed to the fatal injuries 13 days later in Singapore, where autopsy was done.

MLR findings by gynaecologist at Safdarjung Hospital, Delhi – Assault history and related events were told by the victim herself. Blunt trauma abdomen with sexual assault with complete perineal tear and hemoperitoneum with small and large bowel injury noted. She had suffered a perineal tear, a tag of vagina 6 cms in length was hanging outside the introitus, there was profuse bleeding from vagina and in the posterior vaginal wall there was a tear of about 7 to 8 cms, rectal tear of about 4 to 5 cms communicating with the vaginal tear was also visible on local examination. Tears in the vagina, rectum and bleeding per vaginum noted. Various bite marks have been observed on her face, lips, jaw, near ear, on the right and left breasts, left upper arm, right lower limb, right upper limb. The patient was immediately referred to the OT for complete perineal repair.

Surgical notes: Duodenum, jejunum and ileum were contused, jejunum and ileum were of doubtful viability. Large bowel contused, bruised and of doubtful viability, sigmoid colon and rectum were lacerated at many places linearly, mucosa was detached completely, and portion of around 10 cm was prolapsing through the perineal wound; retroperitoneal hematoma present, rectovaginal septum was completely torn. Samples taken of outer and inner clothings; dust and grease present in hairs, nail clippings, breast swab form bite marks, swab from saliva, combing of pubic hair, matted public hair, cervical swabs, washings from vagina, vaginal cultures, rectal swab, oral swab, blood samples sent for FSL.

Dying declaration were recorded thrice during ICU stay, by judicial magistrate after taking fitness for statement from ICU consultant.

PM findings by Singapore gynaecologist: Multiple abrasions and Bruises were noted in inner thigh (groin), right lower thigh, left thigh lateral, left lower anterior, genital; further abrasions and bruise on all parts of the body.

Cause of death Unnatural death after Sepsis with multiple organ failure following multiple injuries.

Defense: Patient was not fit for making the statement, injuries mentioned in the MLC and the PM report can generate severe pain, and without the administration of morphine a patient cannot bear such pain. Patient had endotracheal tube in larynx and trachea and was on ventilator and hence could not speak. None of the statements given by the prosecutrix can be treated as dying declarations since the prosecutrix was never administered oath, does not bear the signature of the victim and contains only her thumb impression and hence her dying declarations are not admissible in evidence. As mentioned in PM report, Patient died due sepsis, which may be due to unhygienic conditions in the govt Hospital.

Court decision: Analysis of the medical evidence of MLR and PM findings clearly show, beyond any reasonable doubt, that the injuries sustained by the prosecutrix were extremely severe and would cause death in the ordinary course of nature, and that death ensued on account of her injuries and not due to any other cause, as alleged, such as unhygienic conditions in the hospital. Since the victim was shivering and was cold on account of the loss of blood due to violent trauma, so instead of taking her signature, doctor asked the victim to give her thumb impression for consent, and its accepted as her dying declaration. Since ICU doctor specifically states that injection morphine was not given to the patient, i.e. on the day on which her statement was recorded, which was verified by ICU recovery chart. It is also relevant to note at this juncture that the evidence of the PM doctors has been recorded through video conferencing from Singapore.³

Purpose of Autopsy

PM examination must be thorough, complete, examining all the body parts from front to back, dissecting all the body cavities for the purpose of diagnosis of cause of death and duration of time since death, to corroborate and substantiate the evidences of the eye witnesses as and when required.

Perinatal deaths

Questions answered by Autopsy findings:

Q. Whether there was any negligence while conducting delivery?

Q. Whether death of the deceased was due to negligence of doctor?

Case law on autopsy proving negligence resulting in Perinatal death.

Facts: Full term pregnant patient with obstructed labor, attempt by vacuum extractor failed. Doctor conducted forceps delivery and a still born baby was delivered. Immediately after the delivery the patient had profuse bleeding due to fatal injury to uterus. The patient died within five days inspite of treatment.

Allegations: After delivery, the doctor should have initially assessed the cause of cervical tear and possibility of rupture of uterus. The patient had pain, distension of abdomen, tachypnoea and tachycardia for 5 days i.e till her death.

PM exam findings: Abdominal cavity contained 2.5 litres of fluid blood and 500 gm. of blood clots (dark red colour). Rupture of uterus 15 X 10 cm, obliquely placed involving full thickness including peritoneum on the posterior surface of the lower segment of uterus, communicating at its lower part with the injury. Its edges were thinned out with ragged appearances. The ruptured area was seen covered with blood clots, dark red in color. Multiple infected superficial lacerations over an area involving the right labia minora. Sutures infected lacerated wound 4 cm long obliquely placed on the right posterior surface of the cervix. Air passages pale and contained illegible frothy fluid.

Cause of death-death was due to complications following rupture of gravid uterus.

Defence: Doctors contended that, patient died because of numerous complications which was mostly due to the irresponsible acts and omissions on the part of the lady and her husband who did not care for anemia.

Decision: On the basis of evidence and the Post mortem report the court held gynaecologist and hospital for deficiency in service as they have failed to diagnose cause of profuse bleeding earlier and their treatment fell below the standard of medical practice and not taken reasonable care during conducting delivery causing the death of the patient, so doctors are directed to pay Rs.1,61,000/-. This is a deficiency in service resulted in medical negligence for which doctor are liable for the loss of two lives, mental agony and psychological trauma,

so doctors to pay punitive cost of Rs.1,00,000 to deceased patient's family.⁴

Discussion: Court observed- it appears that, the doctor applied the forceps negligently, due to which the cervix pulled by traction leading to extension of cervical tear up to the fundus of uterus i.e. rupture of uterus. The PM report confirms the antemortem injuries as rupture of uterus and tears in birth canal.

Do's and Don'ts in Medicolegal Autopsy to avoid legal punishment

- PMR should be prepared by RMP only (PMR - RMP) mirror reflection.
- Never issue death certificate without PM in suspected foul play- Always intimate the police for unnatural death noticed - Not informing police- to screen offender (S.201 IPC - 7 years jail).
- Never manipulate with PM findings- its punishable (S. 197 IPC = 3 years jail).
- Never make false entries in PM- fabrication of evidence (S. 191 IPC = 7 years jail).

PMR <=> RMP Mnemonic for easy recall: (PMR - RMP) mirror reflection of words. PMR should be prepared by RMP only. Post mortem Reporting prepared by registered Medical practitioner only.
--

Fig. 2:

The mirror does not reverse images from left to right, it reverses them from front to back relative to the front of the mirror.

Doctor punished for manipulating Post-Mortem report.⁵

Police arrested victim for illegal Prostitution- Date occurred due to custodial torture- Doctor doing PM, manipulated the findings for simulating natural death- Doctor found guilty and punished 7 years imprisonment.

“This is a case of custodial death and it is seen from the records that the discrepancies found between the 1st and 2nd post-mortem reports, in the considered opinion of this court, are the basis for the prosecution case to make it fit for consideration. There cannot be much difference between two post-mortem report unless manipulation is made in any one of the post-mortem reports.”

Tips for Handling PMR documents

- Never share PM report with anyone online on social media (Whatsapp/facebook/Telegram) - it a confidential legal document- can't be issued/shared under Right to information.
- PMR should be kept in safe custody- if PMR lost/stolen - destruction of evidence (S. 204 IPC = 3 years jail).
- No overwriting in PMR, if any word corrected, it should be initialled by signature of doctor on the original and carbon copies too.

Discussion

The medico legal work these days like modern day life is very much complicated. Disputing a scientifically correct but unfavorable report has become a part and parcel of the medico legal culture. Trend to get the medico legal results hurriedly in a desired fashion that too authoritatively, is as common as it is to reject an unfavorable opinion. The medico-social issues related to medico-legal performance include:

Risky: Medico legal work at times is very difficult and risky because there are more probabilities of one's being disputed, criticized and challenged by many on many occasions for many reasons.

Controversy: The medico legal work is highly controversial. Both the aggrieved and the opposite party seem to be keen to interpret the medical observations to their benefit and interests and mismatching of the medico-legal opinions with the desires and expectations of the people is therefore not uncommon with emergence of many types of disagreements and disputes.

Delicate: Medico legal work is very delicate because if an innocent is involved unnecessarily or a crime goes unnoticed due to faulty application of the medical knowledge would mean different to different persons. It will irk all kinds of people including police, judiciary and the departmental peers.

Public outcry: Political workers and social activists are often up in arms in the so called cases of police torture, hospital or dowry related deaths especially when the medical opinion is different and contrary to the populous opinion and the doctor's failure to act in their favor brought a charge that the doctor for his ulterior motives had worked in collision.

Administrative hypocrisy and juggleries: The legal presumption is that the hospital and the district administrators of health department who are senior to those doing medico legal work by virtue of their age in the department are superior for all practical purposes. This sense of superiority seems to be on the basis of seniority of service and not the specialization and the experience in a particular line. Problems may arise when they either respond inadequately or do not respond in a manner, as they should while giving opinions.

Conclusion

PMR is confidential legal document. Don't rely on just your visual memory neither in writing PMR reports, nor in giving court evidence - always review your PMR before answering any legal queries. Save our career as doctors by proving accused's crime by timely meticulous Medical documentation of burn during PMR after death, and better to inform police in critically ill burned victims for dying declaration in ante-mortem stage only. In current scenario of medicolegal litigation against doctors, courts are giving hefty amounts in Crores in medical negligence but gives meagre amounts in thousands to victims of crime as per IPC. Eg.; a victim of acid burn will get fixed amount for covering treatment expenses from State Government, but if acid attack victim patient files negligence suit against doctor, who has treated his/her best facility, but scar will remain on face, and consumer court will find fault in medical documentation of consent or records and award hefty amounts to be paid by doctor to victim. Burn victims goes for out of court settlement with accused by taking money, and than files medical negligence case against doctor to claim compensation for alleged negligence in reporting crime, or for permanent damages due to injury. If the doctor reports crime by proper documentation and works for the law, doctor can safeguard his career and his reputation during false allegations and accusations of malpractice.

Conflict of Interest: Nil

References

1. Karmakar, RN. Procedures of Medicolegal report writing. 1st Ed. Academic Publishers. Kolkata.
2. Modi, JP. Kannan K. Textbook of Forensic Medicine and Toxicology. 25th Ed. LexisNexis. 2015. Delhi.

3. Supreme court decision in State Vs Ram singh, SC No. 114/ 2013. <https://indiankanoon.org/doc/175704516/>.
4. National Consumer Disputes Redressal in Dr. Prabha Nair and Ors. vs Sri Mohan and Ors. on 20 May, 2013. <https://indiankanoon.org/doc/33132711/>.
5. <https://medicdialogues.in/custodial-death-in-jail-doctor-sentenced-to-7-year-jail-for-post-mortem-manipulation/>.
6. Singh, Mandakini. *Playing by The rules. An update on Govt policies, regulations and acts for practising Gynaecologists.* 1st Ed. CBS publishers. Delhi. 2015.
7. Tiwari S. Kuthe, Alka. *Textbook of Medicolegal issues.* 2nd Ed. Jaypee Publishers. Delhi. 2018.
8. Sankhla, Mahipal Singh. <https://legaldesire.com/medico-legal-postmortemautopsy-in-india-purpose-benefits/> (Access 19/11/2019).
9. Sections 174 & 176 of the Code of Criminal Procedure, 1973. In: Basu's Criminal Court Handbook containing Criminal Major Acts, 10th ed 2007. Orient Publishing Company, New Delhi: 134-36,112-13.
10. Curran WJ. The Medico-legal autopsy and Medico-legal investigation. *Bull N Y Acad Med* July 1971;47(7):766-75.
11. Knight BH. The Forensic Autopsy. In: *Forensic Pathology.* Edward Arnold 1995:1-46.
12. Bhullar DS, Gorea RK, Aggarwal AD. Medico-Legal Autopsy by Panel of Doctors Present Scenario. *JIAFM*, 2004;26(3): 113-16.
13. Pillay,VV. *Textbook of Forensic Medicine and toxicology* 18th Ed, 2017.pp.281-2.