

Histopathological Spectrum of Kidney Lesions in an Autopsy 2 Years Study at Tertiary Care Hospital

Radha R. K.¹, Prathima. S.²

How to cite this article:

Radha R. K., Prathima. S. Histopathological Spectrum of Kidney Lesions in an Autopsy 2 Years Study at Tertiary Care Hospital. Indian J Forensic Med Pathol.2024;17(1):19-23.

ABSTRACT

Autopsy survey of 110 cases of kidney specimen over a period of 2 years done in Vyedhi institute of medical science and Research centre, Department of Pathology, Bangalore. Kidney diseases are due to sequelae of primary or secondary accumulation of risk factors such as diabetes, hypertension, dyslipidaemia and obesity. Autopsy helps in the establishment of diagnosis and determines the cause of sudden death of known and unknown aetiology. Histopathological examination of renal tissue in autopsy gives valuable information for identifying the risk factor for various renal diseases and to monitor the disease trends.

KEYWORDS: Autopsy; Kidneys; Histomorphology; Glomerular disease; Risk factor.

INTRODUCTION

Autopsy is still an important diagnostic procedure despite improvements in ante mortem diagnosis and modern diagnostic facilities available, missed diagnosis discovered during autopsies is still as high as 44.9%.¹ Henriksen postulated that the examination of kidney and the interpretation by the pathologist is a factor of

training in renal pathology and experience. The findings at post-mortem examination of the kidney might be crucial for the family members of the deceased especially those with genetic components as the kidney is rarely biopsied in many medical renal diseases in critically ill patients.²

Some of disease are only diagnosed at autopsy as they don't cause any functional derangement. Medical renal diseases are frequent during autopsies, most of them are unnoticed cases brought for examinations although they are mostly under recognized and significant diagnosis can be missed as well. Thus the autopsy provides a unique opportunity to confirm the clinical suspicion of medical renal disease, establish the effect of systemic disease on the Kidney and also diagnose the occult renal pathology.²

This study emphasizes on various disease that are seen in the kidney at autopsy includes

Author's Credentials: ¹Associate Professor, ²Professor and Head of Department, Department of Pathology, Vydehi Institute of Medical Sciences & Research Center, Bangalore 560066, Karnataka, India.

Corresponding Author: Radha R. K., Associate Professor, Department of Pathology, Vydehi Institute of Medical Sciences & Research Center, Bangalore 560066, Karnataka, India.

Email: drradhark@gmail.com

Received on: 25-01-2024

Accepted on: 30-03-2024

glomerular diseases, tubulointerstitial diseases and vascular diseases. Histopathological features of acute tubular necrosis and arterionephrosclerosis also studied in the autopsy kidneys. Hence this study was conducted to assess the histopathological spectrum of renal lesions and the frequency of various renal lesions.

AIMS AND OBJECTIVES

The main aim of this study was to analyze the histopathological spectrum of renal lesions and to find the frequency of various renal lesions and to categorize the renal lesions according to the histomorphological findings in relation to sex and age.

MATERIAL AND METHODS

Retrospective study was conducted on renal specimens of 110 routine autopsies received in Vyedhi institute of medical science and Research centre, Department of Pathology, Bangalore were examined grossly as well as microscopically. Post-mortem examinations were being done in our institution for common cases are road accidents, drowning, hanging, poisoning and with death due to chronic medical disease. Kidney specimens were mostly received as part of examination of multiple viscera. The medical history and clinical history was recorded. The received specimens of kidneys were fixed in 10% formalin, weighed and dimensions measured were recorded. A minimum of two sections per kidney were studied. All the histological sections were stained in H & E stain & mounted. All the histological sections were examined microscopically & findings were recorded and tabulated.

RESULTS

A total of 110 cases which was sent for kidney autopsies a maximum of male cases were seen. Males constituted 81 percent (89 cases) and Females, 19 percent (21 cases), the male to female ratio was 4.23:1. The series had 66 cases (60%) without any remarkable pathology in the kidney tissue. Congestive changes, a non-specific common feature in autopsies in various organs, were found in the renal tissue in 18 cases (16.3%). The remaining 26 cases with definitive Kidney lesions were examined. Out of 26 cases, 4 cases of Glomerulosclerosis (3.6%), 2 cases of Glomerulonephritis (1.8%). The common pathologies were the predominant involvement of

tubular and interstitial components in 20 (18.1%) cases. In these 1 case of Tubular Hemorrhage (0.9%), 11 cases of Tubular Necrosis (10%), 2 cases of Pyelonephritis, 1 case of Interstitial Nephritis (0.9%), 1 case of Renal Arteriosclerosis (0.9%), 2 cases of Simple cyst (1.8%). There were 2 cases that had involvement of all components of renal tissue (ESRD) and only one case of (0.95%) cases with only vascular lesions.

DISCUSSION

The term autopsy is derived from the Greek word "autopsies" meaning auto (oneself) and ophis (eye) which is "to see for self." Medico-legal autopsies are a mandatory specialized surgical procedure conducted on the corpse to determine the cause of death. Autopsy remains an important tool for the quality assessment of clinical diagnosis. Various findings, unrelated to the cause of death may be noticed during histopathological examination of various organs and tissues retrieved during autopsies. It is important that pathologists pay attention to kidney examination as most medical renal lesions are likely to be missed. The frequency of Renal lesions in autopsy kidneys tabulated in Table 1

Table 1: Frequency of Renal lesions in autopsy kidneys

Histomorphological Findings	Males	Females	% of Cases
I. GLOMERULAR LESIONS			5.4%
• Glomerulosclerosis	4	0	
• Glomerulonephritis	2	0	
II. TUBULAR LESIONS			13.6%
• Tubular Hemorrhage	1	0	
• Tubular Necrosis	9	2	
• Pyelonephritis	1	1	
• Interstitial Nephritis	0	1	
III. VASCULAR LESIONS			0.9%
• Renal Arteriosclerosis	1	0	
IV. RENAL CELL CARCINOMA	0	0	0%
V. OTHERS			3.6%
• Simple Cyst	1	1	
• End Stage Renal Disease	2	0	
• Nephrolithiasis	0	0	
VI. NORMAL HISTOLOGY	53	13	60%
VII. CONGESTION	15	3	16.3%
TOTAL: 110 CASES	89	21	

In the present study the maximum number of cases were seen in the age group 21-40 years (42.7%) which were similar to studies conducted by Amandeep *et al*³ and Sapna *et al*⁴. And Study done by Jesu *et al*⁵ showed the age ranged from 17 to 70 years with male predominance. Maximum deaths occurred in the age group between 31 and 35 years and males were affected more than females. They attributed the higher age group involvement to the demographic pattern of the population with higher elderly population. (Table 2) In the present study, Kidney lesions are predominate in males (89%) and females (19%). Several authors have reported male preponderance (shown in Peichart) All histopathological findings of renal autopsy of present study is compared with the study Amandeep *et al* (2018)

In current analysis in 66 (60%) cases the microscopic findings were close to normal histology. The studies conducted by Amandeep *et al* (2018),³ Vaneet *et al*.¹¹ Utsa *et al*⁸ (2014). Show lesser in number, this could be due to the fact that their study was a specially designed clinical autopsy series to find out renal diseases that go unrecognized. (Table 2).

Table 2: Comparable study- Maximum affected age group

Sl. No.	Study	Age Group
1	Jesu et al (2014)	31-35
2	Sapna et al(2016)	21-40
3	Amandeep et al (2018)	21-40
4	Present Study (2021)	21-40

SEX DISTRIBUTION OF CASES

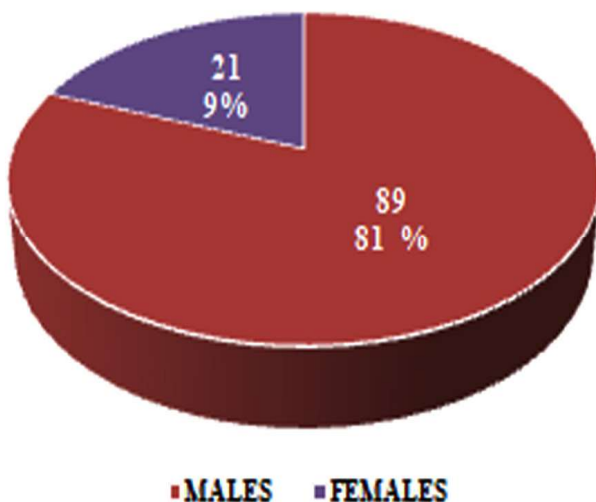
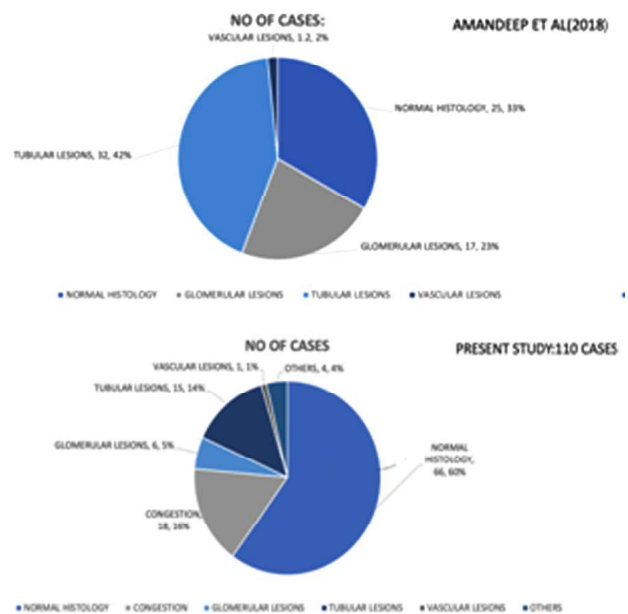


Table 2: Comparison of percentage of normal histology in various studies.

Sl. No	Study	Cases
1	Vaneet et al (2017)	27 out of 120 cases (22.5%)
2	Utsa et al (2014)	23 out of 55 cases (41%)
3	Amandeep et al(2018)	25 out of 100 cases (25%)
4	Present Study 2021	66 Out of 110 cases (60%)

COMPARISON BETWEEN STUDIES



The Chronic kidney disease is now recognised as a major global public health problem and is an independent risk factor for cardiovascular disease and affecting 10-15% of adult population worldwide. In the present study, nephropathological changes were seen in 40% of renal autopsies. The Glomerular changes (Fig. 1) were present in 6 cases (5.5%). The studies by Monga *et al*.⁶ (20%) and Hailmariam S *et al*⁷ (28%) showed slightly higher percentage of renal lesions. (Table 3) In our study it is less, the reason we analysed only histomorphological changes in all renal lesion autopsy kidneys.

Table 3: Comparison of percentage of Glomerular lesions in various studies

Sl. No	Study	Cases
1	Monga et al (1997)	25 cases out of 120 (20%)
2	Hailmariam S et al (2001)	67 cases out of 237 (28%)
3	Amandeep et al (2018)	17 cases out of 100 (17%)
4	Present Study (2021)	6 cases out of 110 (5.5%)

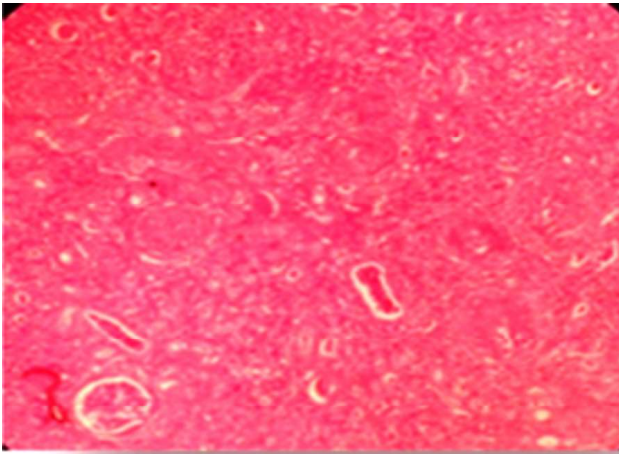


Fig. 1: H&E, 10X The microscopic picture show Glomerulosclerosis

In our series among kidney lesions the predominant diagnosis was tubular necrosis 11 cases and etiology was trauma, sepsis, endogenous toxins and shock. Acute tubular necrosis is seen on histology as disruption of the lining epithelium of the tubules (Fig. 2) This is the most common cause of clinical Acute Kidney Injury (AKI) in hospitalized patients and it could be ischaemic or toxic. It results commonly from hypotension, sepsis, endogenous toxins and nephrotoxic drugs such as antibiotics and chemotherapeutic drugs. It is not easy distinguishing autolysis from AKI from autopsy samples. Autolysis commonly is more widespread, show complete detachment of the tubular cells in the lumina with preservation of the brush borders that are easily demonstrated on PAS stain.

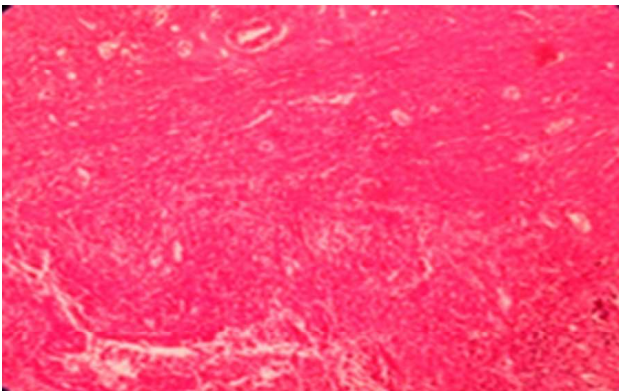


Fig. 2: H & E, 10X, The microscopic picture show tubular necrosis

In present study, the involvement of tubular and interstitial components was found in approximately 20 (18.1%) cases. Among 20 cases the 2 cases (1.8%), with end stage renal disease involving all the components of renal tissue. Chronic pyelonephritis is a descriptive term that refers to the presence of chronic inflammation within the tubules and interstitium and scarring due to bacterial infection

(Fig. 3) It could be obstructive or non-obstructive.¹⁰

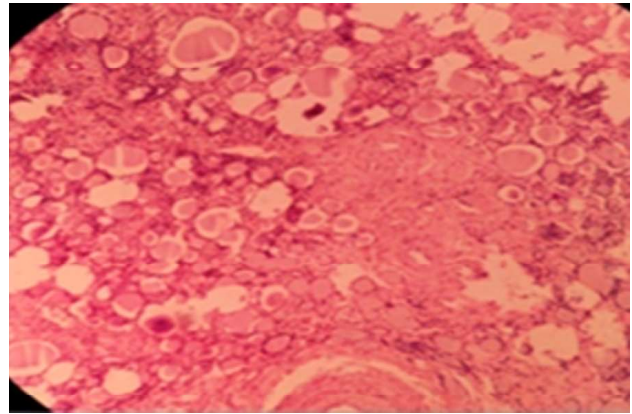


Fig. 3: H&E, 10X The microscopic picture show pyelonephritis

There were two (3.6%) cases of cyst presented with incidental findings (Fig. 4) with and one case (0.62%) of arteriosclerosis. Most studies confirm that atherosclerotic involvement of the intrarenal vasculature is common in the elderly population.⁹

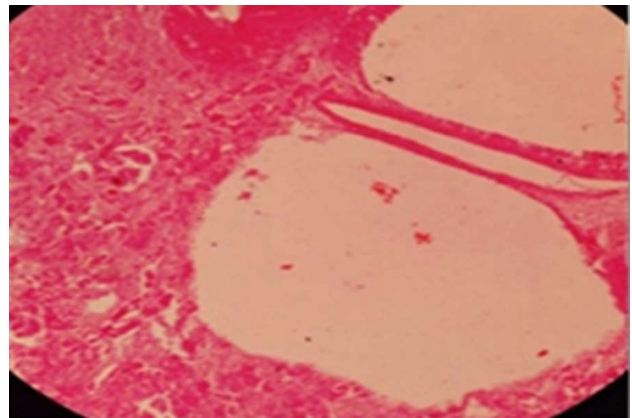


Fig. 4: H&E, 10X The microscopic picture show renal cyst lined by flat epithelium

In the present study was observed 18 (16.3%) cases congestion of kidney in the interstitial space and glomeruli (Fig. 5) was observed due to electrocution, road traffic accidents and trauma.

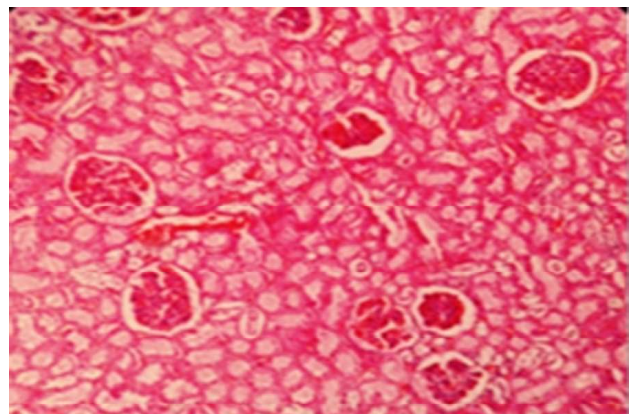


Fig. 5: H&E, 10X The microscopic picture show congestion

In summary the most common findings are of near normal histology and congestion followed by non glomerular lesions and glomerular lesions. The autopsy provides a valuable renal pathology educational tool, as a wide range of medical renal lesions can be seen from kidneys examined at post mortem. It is known that complication of CKD and AKI includes cardiovascular diseases, death and ESRD.

CONCLUSION

The study highlights the various lesions of kidney found in renal tissue obtained on autopsy. Histopathological examination of autopsy kidney lesions helps in identifying cause of death of known and unknown etiologies. Common causes can be identified, and preventions can be taken at earlier stages to either reduce the occurrence of the disease by reducing risk factors or by reducing the advancements of the disease.

KEY POINTS

1. Kidney is vulnerable to a wide variety of

autoimmune, metabolic, toxic, microbial and circulatory insults.

2. Henriksen postulated that the examination of kidney and the interpretation by the pathologist is a factor of training in renal pathology and experience.
3. Prevalence of Chronic kidney disease (CKD) from hospital studies is high and ranges from 11.4 to 26% cardiovascular disease and mortality risks are significantly increased in patient with end stage renal disease (ESRD) and CKD worldwide.
4. The Use of autopsy findings in conjunction with other scientific methods and investigate techniques remains as valuable today as it was centuries ago, both in daily practise and for scientific endeavour.

Conflict of Interest: Nil

Source of Funding: Nil

Ethical issues: Nil

REFERENCES

1. **Nichols L, Aronica P, Babe C.** Are Autopsies Obsolete? *Am J clinPathol.* 1998;110(2):210–218.
2. **Henriksen KJ.** Autopsy kidneys : an overlooked resource. *Autops Case Rep.* 2018;8(1):8–10.
3. **Kaur, Amandeep & Bodal, Vijay Kumar & Garg, Puneet & Aggarwal, Akash. (2018).** *Histopathological Spectrum of Kidney Lesions in Autopsy – A Study of 100 Cases.* 6. 696-699. 10.18535/jmscr/v6i2.150.
4. **Sapna Patel, B.R. Rajalakshmi and G.V. Manjunath** *Histopathologic Findings in Autopsies with Emphasis on Interesting and Incidental Findings- A Pathologist's Perspective J Clin Diagn Res.* 2016 Nov;10(11).
5. **Jesu R Pandian, Rajesh Singh Laishram, Laishram Deepak Kumar, Pinky Phuritsabam, Kaushik Debnath** *Autopsy review of sudden deaths in a tertiary hospital of northeastern India. Journal of Medical Society* 2014; 28(3):145-148.
6. **Monga G, Mazzucco G, Boldorini R, Cristina S, Giacalone A, Fortunato M et al.** *Renal changes in patients with acquired immunodeficiency syndrome. A postmortem study in selected population in northwestern Italy. Mod Pathol* 1997.
7. **Hailemariam S, Walder M, Burger HR, et al.** *Renal pathology and premortem clinical presentation of Caucasian patients with AIDS: An autopsy study from the era prior to antiretroviral therapy. Swiss Med Wkly* 2001;131:412-17.
8. **Utsa U, Tastekin E, Isler E, Kutlu AK, Puyan FO.** *Histopathological and immune alterations in autopsied kidneys. Saudi Med J* 2014;35: 1331-38.
9. **Schiffrin EL, Lipman ML, Mamm JF.** *Chronic kidney disease: effects on the cardiovascular system. Journal of Circulation* 2007; 116:85-97.
10. **Paueksakon P, Fogo AB.** *Autopsy Renal Pathology. SurgPathol.* 2014;7(3):321–355.
11. **Vannet Kaur Sandhu, Arun Puri, Navtej Singh** *The Histomorphological Spectrum of Renal Lesions in an Autopsy Study Annals pathology and Laboratory Medicine Vol 4 no. 4 2017.*

